

**Radicular Cyst Followed By Pulp Therapy In Deciduous Molar : A Case Report**

¹ Dr Shruti Singh, Department of pediatrics and preventive dentistry, Lecturer, Subharti dental college, Swami Vivekanand Subharti University, Meerut.

² Dr Neena Eregowda, Department of pediatrics and preventive dentistry, Lecturer, college of dental sciences, davangere.

³ Dr Poornima P, Department of pediatrics and preventive dentistry, Professor and HOD, College of dental sciences, davangere.

⁴ Roopa K.B., Department of pediatrics and preventive dentistry, Reader, College of dental sciences, davangere.

Corresponding Author: Dr Shruti Singh, Department of pediatrics and preventive dentistry, Lecturer, Subharti dental College, Swami Vivekanand Subharti University, Meerut.

Type of Publication: Case Report

Conflicts of Interest: Nil

Abstract: Radicular cysts are the most common odontogenic cystic lesion of inflammatory origin occurring in jaws. However, those arising from primary teeth are comparatively rare, comprising only 0.5 to 3.3%. Early diagnosis and treatment of inflammatory radicular lesions associated with deciduous teeth is imperative as they can lead to bony expansion and may adversely affect underlying permanent successor. This report presents a case of a radicular cyst associated with a primary mandibular molar following pulp therapy, and discusses the relationship between the pulp therapy and the rapid growth of the cyst and also emphasizes on any adverse impact on underlying permanent successor.

Keywords : radicular cyst; deciduous molar; pulp therapy.

Introduction

Inflammatory jaw cysts comprise a group of lesions that arise as a result of epithelial proliferation within an inflammatory focus due to a number of causes. Radicular cysts are the most common inflammatory cysts arising from the epithelial residues in the periodontal ligament as a result of periapical periodontitis following death and necrosis of the pulp.^[1] These are odontogenic cysts derived from inflammatory activation of epithelial root sheath

residues (cell rests of malassez), arise within a periapical granuloma relating to stimulation resulting from necrotic tooth.^[2] These cysts are usually seen at the apices of the teeth with infected and necrotic pulp.^[1] Radicular cysts are rare in the primary dentition, representing only 0.5–3.3% of the total number in both primary and permanent. Most radicular cysts seen in the primary dentition are associated with mandibular molars.^[3] Radicular cysts associated with deciduous teeth are reported to occur in age range of 3–19 years with a male preponderance.^[4] Caries is the most frequent cause for radicular cyst in deciduous dentition. They may also form following traumatic injuries to primary teeth.^[5] Intracanal medicaments used for pulp therapy and distinctive intraepithelial inclusions found in cyst wall, can also provide a site for continuous antigenic stimulation. Pulpal and interradicular infections in primary teeth have a tendency to drain more readily than those of permanent teeth.^[6] This report presents a case of a radicular cyst associated with a primary mandibular molar following pulp therapy.

Case report

A 13-year-old male patient reported to the Department of Pedodontics and Preventive dentistry with a complaint of

pain and swelling in lower left back region of the jaw since 1 month. Patient had no previous history of swelling, 30 days back he noticed swelling on the lower left back region of face preceded by pain, which gradually increased in size, and there was associated history of occasional pus discharge [Figure 1]. Past dental history revealed that he had undergone incomplete endodontic treatment with the same tooth a year ago. He was overall in good health. Extraoral examination revealed, a diffuse, bony, nontender swelling on left side of jaw extending from corner of mouth to angle of mandible. Intraoral examination revealed grossly carious and mobile mandibular left primary second molar and a swelling of about 1.8 cm X 1.5 cm extending from mesial aspect of 34 to distal aspect of 75 obliterating the vestibule [Figure 2]. Radiographic investigations included periapical radiograph [Figure 3], orthopantomograph (OPG) and occlusal view. Panoramic radiograph showed a well circumscribed round unilocular radiolucent lesion, 2 × 2.5 cm in diameter, extending from distal aspect of 34 to distal aspect of 36 anteroposteriorly, also involving the crown portion of the permanent second premolar tooth bud, below the left second primary molar slightly displacing the successive permanent second premolar laterally [Figure 4,5]. A closer examination of the radiograph revealed that the border of the lesion appeared corticated and was smooth and well-defined. Occlusal radiograph revealed buccal cortical plate expansion extending from distal aspect of permanent mandibular left first premolar to mesial aspect of permanent mandibular left second molar [Figure 6]. From history, clinical and radiological examination a diagnosis of radicular cyst associated with the mandibular left primary second molar was made which could be due to either secondary caries or the medicament used during endodontic treatment. Fine-needle aspiration cytology was performed as chair side investigation with 24 gauge needle, 0.5 ml yellow straw coloured fluid was aspirated and subjected to cytological

examination, which showed mixed inflammatory cells with sparse amount of epithelial cells suggestive of an inflamed cystic lesion [Figure 7].

Differential diagnosis included periapical granuloma or dentigerous cyst. From these findings, the case was diagnosed as radicular cyst associated with the mandibular left primary second molar, caused by the failure of pulp treatment using therapeutic paste. Extraction of the primary second molar and extirpation of the cyst led to uneventful healing, after which the permanent second premolar erupted together with its proximal first premolar [Figure 8]. After thorough curettage of cystic lining, Iodoform dressing was given in the area next day and dressing was changed twice weekly till healing occurred [Figure 9]. Cystic lining was removed as much as was accessible and sent for histopathological examination. Histopathological features were consistent with provisional diagnosis of radicular cyst. Histological examination revealed the cystic cavity to be lined by a non-keratinized stratified squamous epithelium with mixed inflammatory infiltration [Figure 10]. The patient came every 3 months for regular checkup. At 9 months follow-up, tooth had almost aligned vertically and was on the path of eruption [Figure 11]. IOPA and OPG revealed good amount of bone formation [Figure 12,13]. The patient is on a regular follow-up.

Discussion

Most radicular cysts found in the primary dentition are associated with mandibular molars, teeth that are prone to dental caries.^[7] Periapical radiolucency relating to primary teeth tends to be misdiagnosed as a periapical granuloma or a dentigerous cyst from the permanent successors. A comprehensive assessment regarding the position of the permanent tooth germ with radiographic and surgical evaluation followed by a confirmatory histopathologic appraisal may aid in the correct diagnosis. Radiographically, a dentigerous cyst is characterized by a

unilocular radiolucent area that is associated with crown of an unerupted permanent tooth. On the other hand, periapical granulomas are radiographically indistinguishable from radicular cysts. Radicular cyst development is the next stage following formation of periapical granuloma. Furthermore, larger the lesion, the greater the probability it will be a radicular cyst. Nearly all lesions > 2 cm in diameter are diagnosed as cyst.^[6] According to Livingston, the growth rate of a radicular cyst is estimated to be approximately 5 mm in diameter annually. Hill reported that the growth rate of a radicular cyst in the primary dentition was estimated to be 4 mm annually.^[6] In primary molars, cyst is located in interradicular area and around the roots, whereas in permanent incisors, it is usually located at the apex. This can be explained by the short and sometimes partially resorbed roots of primary molars and also the presence of accessory canals. Thus, the term periradicular cyst in primary molars is more appropriate than radicular cyst.^[3] Radicular cysts originating from primary teeth are considered rare. Radicular radiolucencies related to deciduous teeth tend to be neglected and probably resolve after removal of the offending teeth. The frequency is low because pulpal and periapical infections in deciduous teeth tend to drain more readily than those of permanent teeth and antigenic stimuli which evoke the changes leading to formation of radicular cyst may be different.^[7] Radicular cyst in deciduous teeth are reported to occur in age range of 3–19 years with a male preponderance of 1.6:1. The most commonly involved deciduous teeth are mandibular molars (67%), maxillary molars (17%) followed by anterior teeth.^[8] Our case correlates with the age and sex predilection and occurred in relation to deciduous mandibular molar teeth. Grundy et al reported 17 cases of cystic lesions associated with primary molars following pulp therapy and demonstrated that the only constituent common to the pulpal medicaments used in their report was the phenol group present in cresol and

parachlorophenol. The hypothesis by Grundy et al states that pulpal therapeutic agents may cause antigenic necrotic materials within the root canals to provide continuing antigenic stimulation.^[9] Recently it has been reported that pulp therapy in form of calcium hydroxide/iodoform (non-phenol) may also be responsible for stimulation of radicular cysts in deciduous molars.^[6] This does not mean that prohibition of medicaments for pulp treatment of primary teeth is necessary, as the incidence of radicular cysts in primary teeth is extremely low, but based on these data primary molars after pulp therapy should receive periodic postoperative radiographic examination. Histologically, no difference exists between the cysts of primary teeth and those of permanent teeth except for rarity of cholesterol crystal slits associated with primary teeth. This is due to fact that lesion associated with the primary teeth exists for shorter duration before removal as compared to permanent teeth.^[10] Untreated radicular cyst cases may present with swelling, tenderness, tooth mobility and a bluish tinge caused by buccal expansion of the cortical plates. Furthermore, displacement of successor tooth or, the loss of its vitality may result.^[6] The most common clinical and radiographic features of radicular cyst in primary molars include the following:

1. Well-defined circumscribed unilocular radiolucency
2. Mandibular buccal cortical plate expansion
3. Thin reactive cortex
4. Displacement of succedaneous tooth
5. Misleading preoperative diagnosis^[4]

Various treatment modalities advocated for cystic lesions are enucleation, enucleation with curettage, marsupialization, and marsupialization with enucleation. Other modalities include, removable or fixed resin tubes followed by saline irrigation after each meal to prevent fibrous healing and to promote decompression and the use of removable acrylic partial dentures for decompression and space maintenance.

Our case was diagnosed as a radicular cyst for following reasons: presence of large unilocular radiolucency in relation to roots of a nonvital primary tooth, slight lateral displacement of the underlying successive tooth, size greater than 2 cm, histological confirmation of cystic epithelial lining.

Figures

Figure 1 : Preoperative photograph showing mild swelling in lower left side of face



Figure 2 : Preoperative intraoral photograph

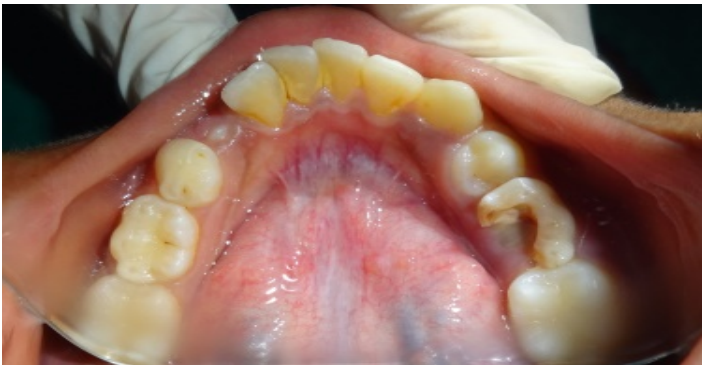

Figure 3 : Preoperative intra oral periapical radiograph with 75 region

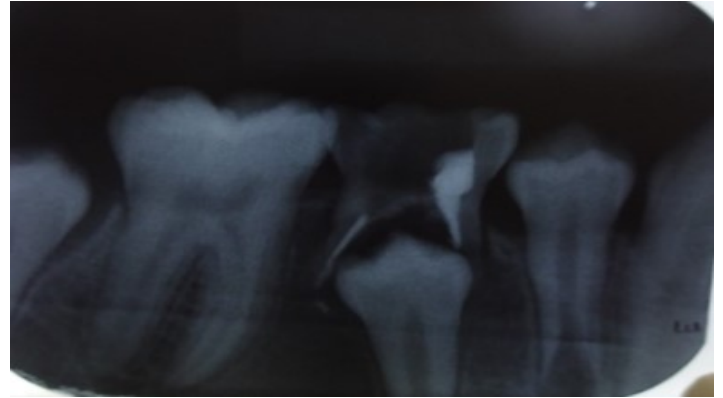


Figure 4 : Preoperative panoramic radiograph showing unilocular radiolucency in left side of jaw

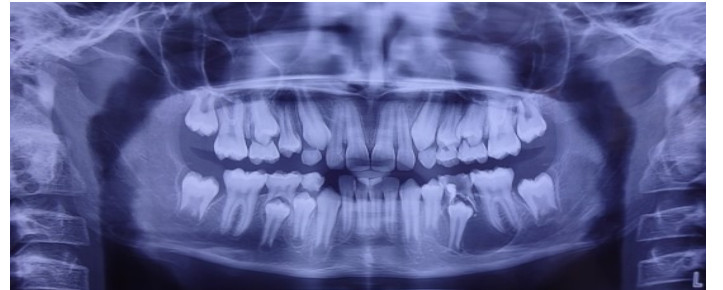

Figure 5 : Close up view of cropped OPG

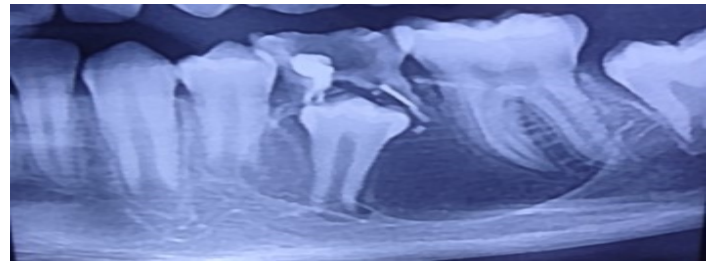


Figure 6 : Occlusal radiograph depicting buccal expansion from middle of 34 to distal aspect of 36

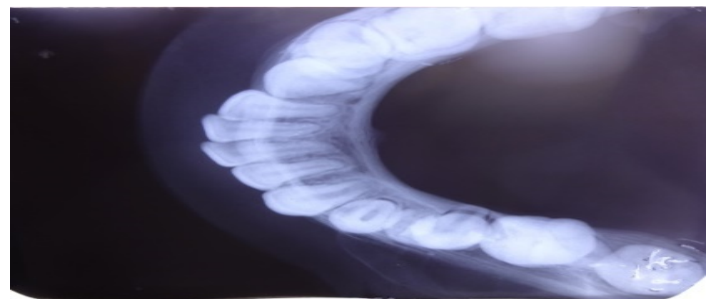


Figure 7 : Aspirated yellow straw colored content

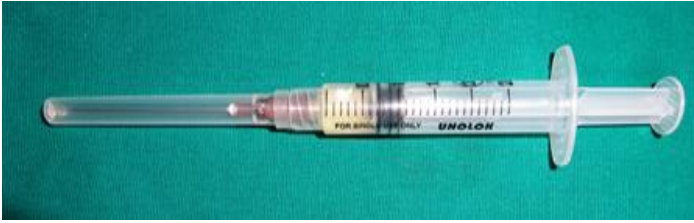

Figure 8 : Extirpated cyst lining

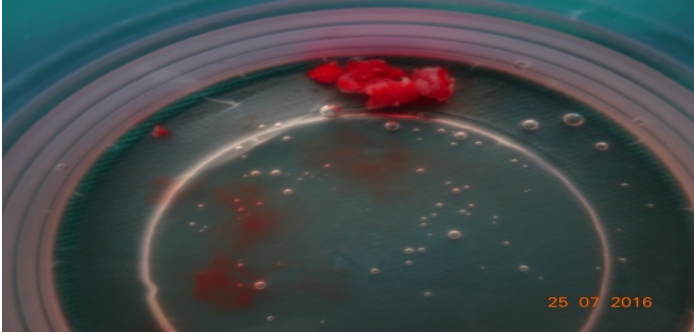


Figure 9 : Post-operative image with soaked iodoform gauze

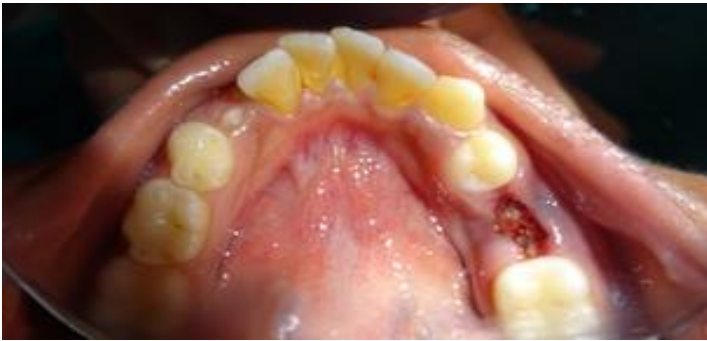

Figure 10 : Photomicrograph of the H and E stained tissue (x10), showing arcading pattern

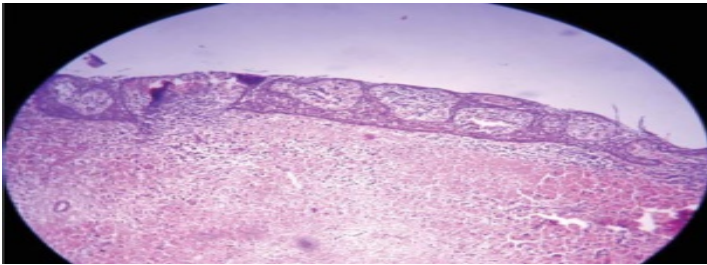


Figure 11 : Post-operative intraoral photograph showing erupting 35 at 9 months follow-up

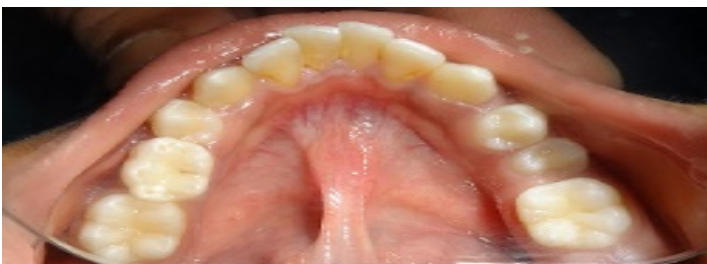

Figure 12 : Post-operative intraoral periapical radiograph depicting adequate bone healing at 9 months follow up

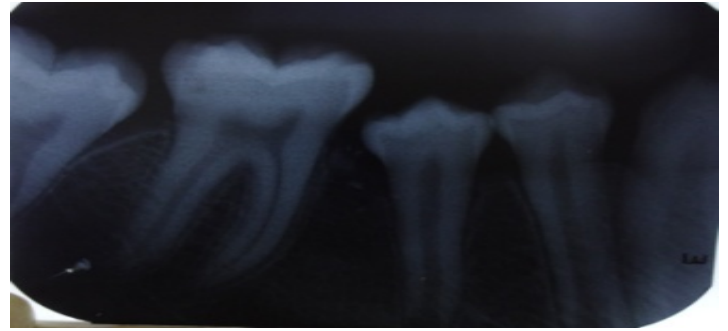
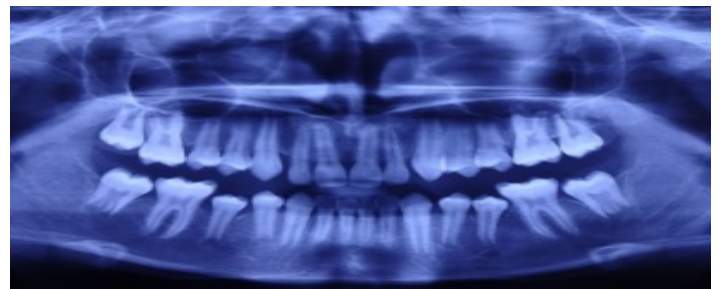


Figure 13 : Post-operative panoramic radiograph depicting adequate bone healing at 24 months follow up



Conclusion :

Given the severity of sequelae of the radicular radiolucent lesion associated with deciduous teeth it is prudent to timely detect and treat these lesions. Regular clinical and radiographic follow-up of endodontically treated primary teeth should be done. Absence of clinical symptoms does not imply that the tooth is healthy. Each treated case should be timely followed up to monitor healing of osseous defect and proper eruption of successive tooth. The reparatory process is completed in one to two years. In children, healing of post surgical osseous defects is always good as they have high propensity for bone regeneration.

References

1. Shear M. Cysts of the oral region. 2nd ed. UK: Butterworth Heinemann Ltd, John Wright & Sons; 1983
2. TenCate A R. The epithelial cell rests of Malassez and the genesis of the dental cyst. Oral Surg Oral Med Oral Pathol 1972; 34(6): 956-64.

3. Ramakrishna Y, Verma D. Radicular cyst associated with a deciduous molar: a case report with unusual clinical presentation. *J Ind Soc Pedod Prev Dent* 2006;24(3):158-160.
4. Lustmann J, Shear M. Radicular cyst arising from deciduous teeth- review of literature and report of 23 cases. *Int J Oral Surg* 1985; 14:153–161.
5. Delbem ACB, Gunha RF, Vieira AEM, Pungliesi DMC. Conservative treatment of a radicular cyst in a 5-year-old child: a case report. *Int J Pediatr Dent* 2003;13(6):447-450.
6. Takiguchi M, Fujiwara T, Sobue S, Ooshima T. Radicular cyst associated with a primary molar following pulp therapy — a case report. *Int J Pediatr Dent* 2001;11(6):452-455.
7. Mass E, Kaplan I, Hirshberg K. A clinical and histopathological study of radicular cysts associated with primary molars. *Journal of Oral Pathology and Medicine* 1995;24:458–461
8. Nagata T, Nomura J, Matsumura Y, Yanase S, Fujii T, Oka T, et al. Radicular cyst in a deciduous tooth: a case report and review of literature. *J Dent Child.* 2008;75:80–4.
9. Grundy GE, Adkins KF, Savage NW. Cysts associated with deciduous molars following pulp therapy. *Australian Dental Journal* 1984;29 : 249–256.
10. Chander VV, Koduri S, Basoya S, Arya L. Radicular cyst of maxillary primary tooth: Report of two cases. *J Oral Res Rev* 2014;6:61-4