



A Clinical Study on Koch's Abdomen Presenting as an Emergency

¹Dr. Hemanth Sai Venkata Chalam Rambha, ²Dr. R. Ashok Reddy

¹PG Scholar, Department of General Surgery, Great Eastern Medical School and Hospital, Srikakulam, Andhra Pradesh, India

²HOD, Department of General Surgery, Great Eastern Medical School and Hospital, Srikakulam, Andhra Pradesh, India

Citation of this Article: Dr. Hemanth Sai Venkata Chalam Rambha, Dr. R. Ashok Reddy, "A Clinical Study on Koch's Abdomen Presenting as an Emergency." IJMSAR – October – 2023, Vol. – 6, Issue - 5, Page No. 01-12.

Copyright: © 2023, Dr. Hemanth Sai Venkata Chalam Rambha, et al. This is an open access journal and article distributed under the terms of the creative commons attribution noncommercial License. This allows others to remix, tweak, and build upon the work non commercially, as long as appropriate credit is given and the new creations are licensed under the identical terms.

Corresponding Author: Dr. Hemanth Sai Venkata Chalam Rambha, PG Scholar, Department of General Surgery, Great Eastern Medical School and Hospital, Srikakulam, Andhra Pradesh, India

Type of Publication: Original Research Article

Conflicts of Interest: Nil

ABSTRACT

Background and Objectives

Abdominal tuberculosis ranks as the sixth most prevalent form of extra-pulmonary tuberculosis. This term encompasses tuberculosis infections affecting the gastrointestinal tract, peritoneum, lymph nodes and solid organs such as the spleen, liver and pancreas. The diagnosis of abdominal tuberculosis is frequently delayed because of its non-specific symptoms and signs. The clinical investigation into abdominal tuberculosis was carried out to assess the occurrence of abdominal tuberculosis, the diverse locations of presentation and the frequency of surgical emergencies stemming from abdominal tuberculosis.

Materials and Methods

The study was conducted in the Department of

General surgery, GREAT EASTERN MEDICAL SCHOOL AND HOSPITAL BETWEEN JUNE 2021 TO JUNE 2023. 50 patients were included in the study. Data were collected from all patients. Patient's age and sex were noted. Detailed history was obtained. Thorough clinical examination was performed.

Every patient had chest x-ray and abdominal x-ray. CT abdomen was performed in inconclusive cases. Tissue diagnosis by histopathological examination had proven positive for all patients. The details of all the patients were collected and analyzed.

Results

Abdominal tuberculosis mostly occurred in the middle

age group (21- 40 years). The most common presenting symptoms are abdominal pain and abdominal tenderness is the most common sign elicited. Ileocaecal region is the most commonly affected region in the abdominal tuberculosis. About 26% of patients had associated pulmonary tuberculosis. Surgery is usually indicated in patients with complications of abdominal tuberculosis. The most common surgical emergency is intestinal obstruction due to either ileocaecal mass or stricture followed by perforation. Limited bowel resection and anastomosis was mostly commonly performed surgery in abdominal tuberculosis followed by adhesiolysis and band release is the most common procedure performed. All the patients are started on anti tuberculosis therapy. Anti- tubercular treatment still forms the mainstay of treatment. All patients started on category I anti tubercular treatment.

INTRODUCTION

Abdominal tuberculosis is sixth most common type of extra pulmonary tuberculosis.[1] Abdominal tuberculosis denotes tuberculosis infection of gastrointestinal tract, peritoneum, lymph nodes, and solid organs i.e. spleen, liver, and pancreas.[2].

Abdominal tuberculosis is a major public health problem in developing countries. The incidence of abdominal tuberculosis is increasing due to increasing incidence of AIDS[3]. it may mimics other gastrointestinal lesions like inflammatory bowel disease, malignancies. The diagnosis is usually delayed due to non specific symptoms and signs.

Abdominal tuberculosis continues to be major cause of mortality and morbidity in our country. We observed the various presentations of abdominal tuberculosis in our hospital and analyzed the

pathology in present scenario. The study was conducted in the Department of general surgery IN GREAT EASTERN MEDICAL SCHOOL AND HOSPITAL BETWEEN JUNE 2021 TO JUNE 2023.

AIM OF STUDY

1. To study various clinical presentations of abdominal tuberculosis.
2. To study sex and age distribution.
3. To study the site distribution.
4. To study the complications of abdominal tuberculosis.
5. To study incidence of abdominal tuberculosis presenting as acute emergencies.
6. To study the most common surgeries performed in abdominal tuberculosis.

MATERIALS AND METHODS

The clinical study of abdominal tuberculosis was conducted with the aim to evaluate the incidence of abdominal tuberculosis, various sites of presentation, incidence of surgical emergencies due to abdominal tuberculosis.

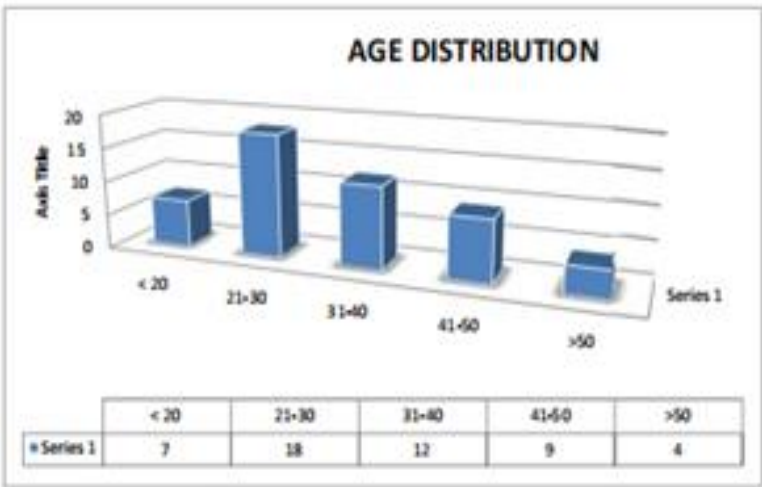
The study was conducted in the department of general surgery in GREAT EASTERN MEDICAL SCHOOL AND HOSPITAL BETWEEN between JUNE 2021 TO JUNE 2023. 50 patients were included in the study pooled from surgical outpatient clinic or emergency department.

Data were collected from all patients. Patient's age and sex were noted. Detailed history was obtained. Thorough clinical examination was performed. Every patient had chest x-ray and abdominal x-ray. All basic blood investigations were done. CT abdomen was performed in inconclusive cases. CT abdomen and colonoscopy was not performed in those who underwent surgical emergencies. Tissue diagnosis by

histopathological examination had proven positive for collected and analyzed.
 all patients. The details of all the patients were

OBSERVATION AND ANALYSIS

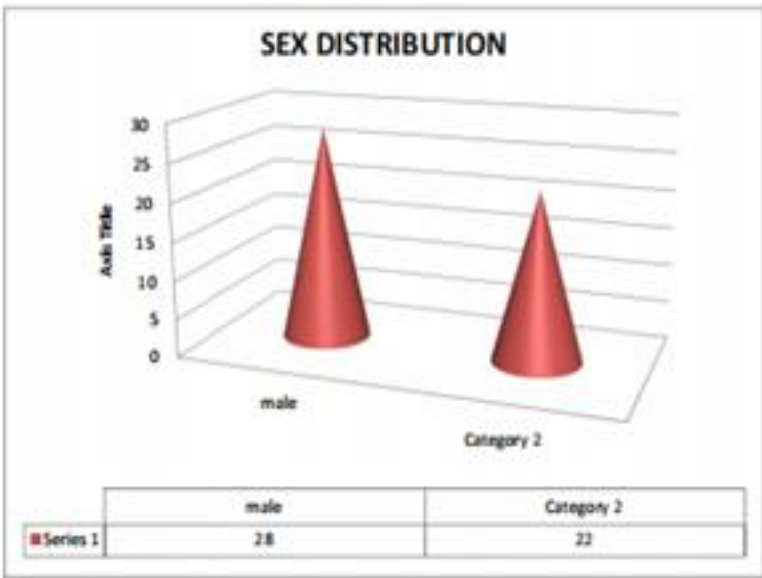
1. Age Distribution



The present series include 50 patients. The youngest patient was 16 year old and the oldest being was 65 year old. The average age of the patient in the series was 32.5% . Age incidence of present series is similar to reported by J.D. Wig et al and Ramesh c. Bharathi et al.

2. Sex Distribution

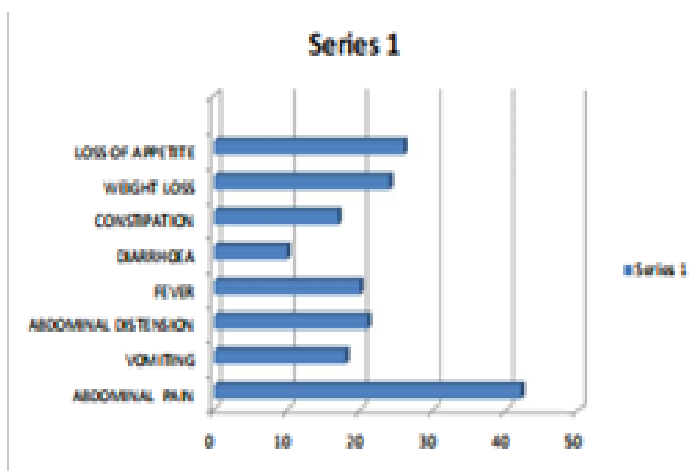
The present study included 28 male patients and 22 female patients



The male to female ratio was 1.2:1 Addison et al reported high incidence in male. M.ismail et al reported equal incidence in both male and female.

3. Clinical Presentation

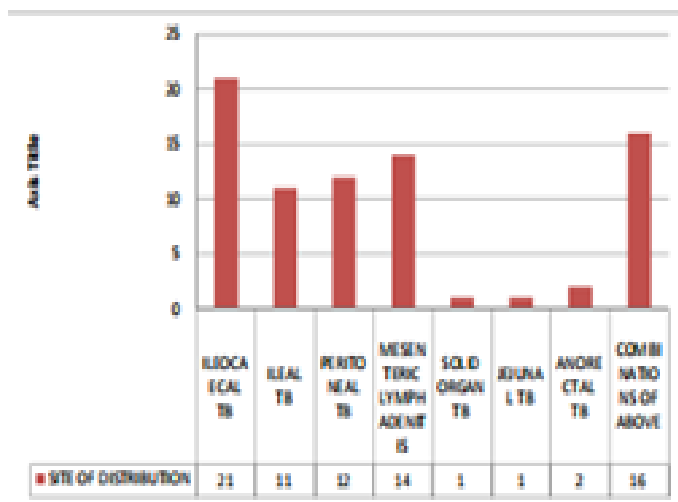
The patient in these series are presented with symptoms ranging from abdominal pain to constitutional symptoms like loss of weight, loss of appetite, fever. The frequency of symptoms are



In the present study, the most common symptoms is abdominal pain (84%) similar to results reported in Das p.Shukla H.S. et al and Bhansali k. et al. other common symptoms are fever, vomiting, bowel disturbances, loss of weight and loss of appetite.

4. Sites of Abdominal Tuberculosis

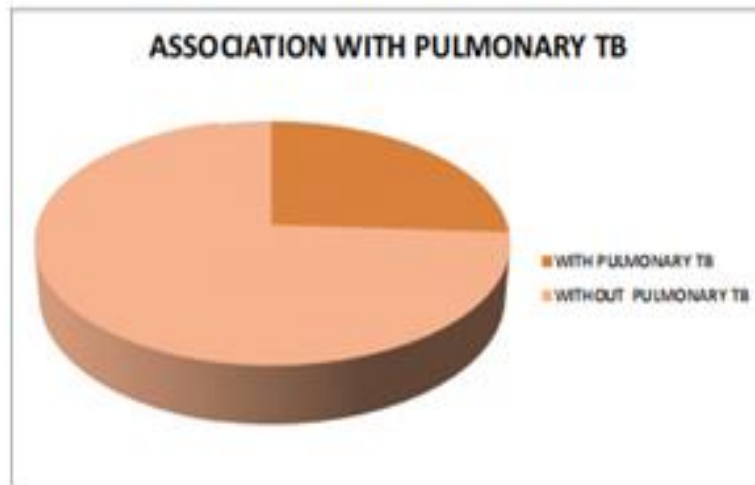
The ileocaecal junction was most commonly affected in abdominal tuberculosis with 42% of patients followed by terminal ileum.



Ileocaecal region is the most commonly affected region in abdominal tuberculosis similar to reports from Chalya et.al. about 42% of patients presented with ileocaecal tuberculosis, followed by mesenteric lymphadenitis and peritoneal tuberculosis.

5. Associated Pulmonary Tuberculosis

In our study associated pulmonary tuberculosis presents in 13 out of 50 patients that is 26%



6. Investigations

x-ray chest PA view taken in all patients. About 13 patients showed evidence of pulmonary tuberculosis.

PLAIN X-RAY ABDOMEN ERECT in emergency conditions showed multiple air fluid level in 11 patients and air underdiaphragm in 6 patients.

ESR done in all patients and elevated in 29 patients indicating the ongoing inflammation. Mantoux test was performed in 30 patients and strongly positive in 17 patients.

CT-Abdomen

CT abdomen was taken in 24 patients. Majority of patients CT picture showed signs of abdominal tuberculosis like lymphadenopathy, irregular soft tissue densities, ascites, bowel wall thickening.

Colonoscopy

Colonoscopy was performed in 18 patients with symptoms of abdominal mass, altered bowel habits, and biopsy confirmed tubercles and characteristic feature of caseating granuloma.

Laparoscopy

Laparoscopy was performed in 8 patients and confirmed by peritoneal biopsy.

7. Surgical Treatment

Surgical treatment was offered to those patients presented with acute emergency conditions like obstruction and perforation. 18 patients underwent emergency surgery.

Emergency surgery for intestinal obstruction was performed in 11 patients. Of which resection and anastomosis was

performed in 3 cases. Adhesiolysis done in 6 cases. Resection and ileostomy was performed in 1 case. Right hemicolectomy done in 1 case.

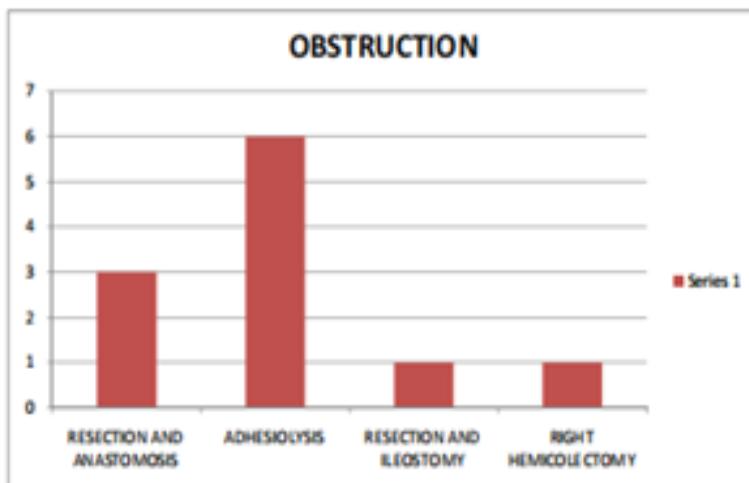
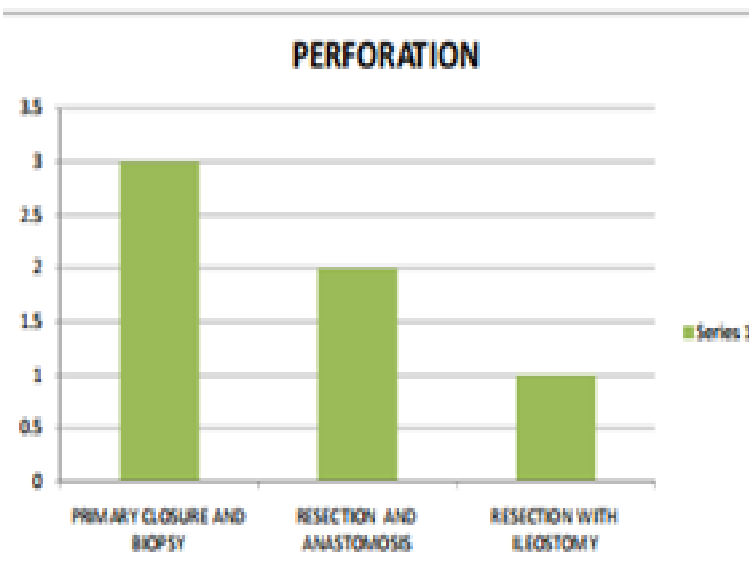


Table: Emergency Surgery In Intestinal Obstruction

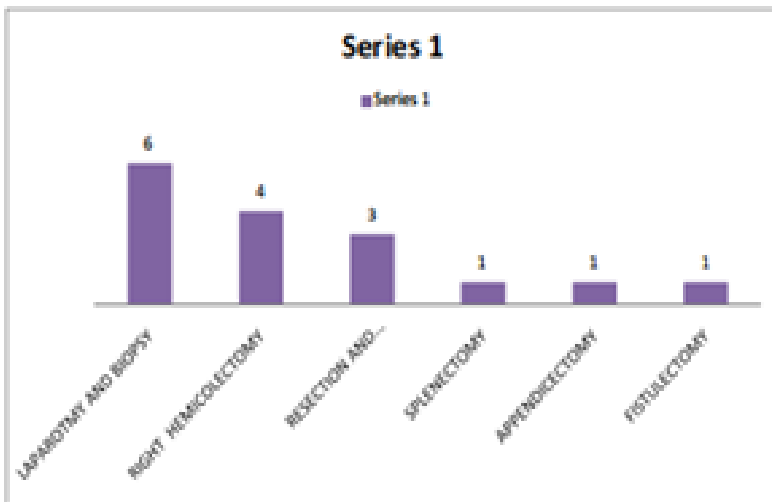
Emergency surgery for perforation was performed in 6 cases. Of which 3 patients underwent primary closure and biopsy. 2 cases underwent resection and anastomosis. One case underwent resection with ileostomy. One patient underwent emergency appendicectomy for appendicular perforation.



Surgeries in Perforation

Elective surgery was performed in 16 patients of whom 6 patients were underwent laparotomy and biopsy alone. Right hemicolectomy was done in 4 patients. Resection and anastomosis was done in 3 patients. One patient underwent

splenectomy for splenic tuberculosis. Two patients underwent fistulectomy for perianal fistula.



DISCUSSION

1. Age Distribution

SL NO	AGE IN YEARS	J.D. Wig et al 1979	RAMESHC. BHARATHI et al 1996	PRESENT STUDY
1.	< 20 YEARS	11(15.06%)	28(21.3%)	7(14.0%)
2.	20-30 YEARS	37(50.7%)	51(38.6%)	18(36%)
3.	31-40 YEARS	15(20.5%)	24(18.6%)	12(24.0%)
4.	41-50 YEARS	6(8.2%)	5(3.8%)	9(18.0%)
5.	> 50 YEARS	4(5.5%)	3(2.2%)	4(8.0%)
	TOTAL	73	132	50

In our present study, most of abdominal tuberculosis presented in the age group of 21-30 and 31-40 which were 36.0% and 24% respectively. Age incidence of present series is similar to reported by J.D. Wig et al and Ramesh c. Bharathi et al. other studies by Sharma et.al 1972 and B.K.Bhansali et.al,1968 also reported Similar age incidence.

2. Sex Distribution

In our study , the male to female ratio is 1.2:1. 28 patients (56%) were male and 22 patients (44%) were female with slight male preponderance. Addison et al reported high incidence in male. M.Ismail et al reported equal incidence in both male and female.

3. Clinical Presentation

SL NO	SYMPTOMS	DAS P.SHUKLA H.S.et al	BHANSALI S.K. et al 1978	PRESENT STUDY
1.	Abdominal pain	94%	100%	84%
2.	vomiting	69.6%	29.9%	36%
3.	Abdominal distension	45%	-	42%
4.	fever	42.2%	49.2%	40%
5.	Diarrhea	16%	21%	24%
6.	constipation	48%	55%	34%
7.	Weight loss	35.6%	25.6%	48%
8.	Loss of appetite	-	42.9%	52%

In the present study, the most common symptoms is abdominal pain (84%) similar to results reported in Das p.Shukla H.S. et al and Bhansali k. et al. other common symptoms are fever, vomiting, bowel disturbances, loss of weight and loss of appetite.

4. Site of Involvement

SL NO	SITE OF INVOLVEMENT	CHALYA et al 2013	PRESENT STUDY
1.	Ileocaecal TB	57.5%	42%
2.	Ileal TB	34.0%	22%
3.	Peritoneal TB	41.4%	24%
4.	Jejunal TB	5.7%	2%
5.	Nodal TB	3.9%	28%
6.	Solid visceral TB	2.7%	2%
7.	Ano-rectal TB	2.3%	4%

Ileocaecal region is the most commonly affected region in the abdominal tuberculosis similar to reports from Chalya et.al. about 42% of patients presented with ileocaecal tuberculosis, followed by mesenteric lymphadenitis and peritoneal tuberculosis.

5. Association of Pulmonary Tuberculosis

In our present study, 13 out of 50 (26%) patients had associated pulmonary tuberculosis which is comparable to reports by bhansali et al (24.8%) and Das P.Shukla et al (27.8%). This indicates that abdominal tuberculosis is not always secondary to pulmonary tuberculosis.

6. Surgical Management

SL NO	SURGICAL PROCEDURE	CHALYA et al	PRESENT STUDY
1.	RELEASE OF ADHESIONS	124(58.5%)	6(17.6%)
2.	BOWEL RESECTION AND ANASTOMOSIS	56(26.4%)	8(23.5%)
3.	RIGHT HEMICOLECTOMY	14(6.6%)	5(14.7%)
4.	PERFORATION CLOSURE	12(5.7%)	3(8%)
5.	ILEOSTOMY	1(0.5%)	2(5.8%)
6.	LAPAROTOMY AND BIOPSY	8(3.8%)	6(17.6%)
7.	SPLENECTOMY	4(1.9%)	1(2.9%)
8.	APPENDICECTOMY	6(2.8%)	1(2.9%)

Surgery was indicated in those patients with complications mostly due to intestinal tuberculosis. In present study, 18 patients underwent emergency surgery. 11 patients were operated for intestinal obstruction and 6 patients for peritonitis due to hollow viscus perforation. 16 patients underwent elective surgery. Antitubercular therapy is the mainstay of the treatment along with improvement of nutrition. All the patients started on category I antitubercular therapy under RNTCP GUIDELINES

CONCLUSIONS

1. Abdominal tuberculosis mostly occurred in the middle age group (21- 40 years)
2. The most common presenting symptoms is abdominal pain and abdominal tenderness is the most common sign elicited.
3. Ileocaecal region is the most commonly affected region in the Abdominal tuberculosis.
4. About 26% of patients had associated pulmonary tuberculosis.
5. Surgery is usually indicated in patients with complications of abdominal tuberculosis.
6. The most common surgical emergency is intestinal obstruction due to either ileocaecal mass or stricture followed by perforation.

7. Most of the patients are diagnosed using CT ABDOMEN and colonoscopy guided biopsy.
8. Limited bowel resection and anastomosis was mostly commonly performed surgery in abdominal tuberculosis followed by adhesiolysis and band release is the most common procedure performed.
9. All the patients are started on anti tuberculous therapy. Anti tubercular treatment still form the mainstay of treatment. All patients started on category I anti tubercular drugs based on RNTCP guidelines.

REFERENCES

1. Peda veerraju E. Abdominal tuberculosis. In : Textbook of pulmonary and extrapulmonary tuberculosis. 3rd edition. New Delhi: interprint 1998 p.250-2.
2. Addison N.V. & J.M. Findlay. Abdominal Tuberculosis. Current Surgical practice vol. 3 page, 48-61(1982).
3. Goldman KP. AIDS and tuberculosis. *Tubercle* 1988; 69: 71-2.
4. Tan K-K, Chen K, Sim R: The spectrum of abdominal tuberculosis in a developed country: a single institution's experience over 7 years. *J GastrointestSurg* 2009, 13:142–147.
5. Rathi PM, Amarapurakar DN, Parikh SS, Joshi J, Koppikar GV, Amarapurkar AD, et al. Impact of human immunodeficiency virus infection on abdominal tuberculosis in western India. *J Clin Gastroenterol* 1997;24 : 43-8.
6. Sharma MP, Bhatia V: Abdominal tuberculosis. *Indian J Med Res* 2004,120:305–315.
7. Tandon HD, Prakash A. Pathology of intestinal tuberculosis and its distinction from Crohn's disease. *Gut* 1972; 13 :260-9.
8. Kapoor VK. Abdominal tuberculosis. *Postgrad Med J* 1998;74 : 459-
9. Sheen-chen SM. Chou FF. Wan YL. Eng HL. Tuberculosis presenting as Solitary splenic tumour. *Tuber Lung Dis* 1995: 76: 30-3.
10. Brusko G. Melvin VS. Fromekes JJ, Ellison EC, pancreatic TB *Ann surg* 1995: 61:513-15.
11. Levine R. Tenner S. Steinberg W. Ginsberg A. Bomm M. Huntingroti D. Tuberculous abscess of pancreas. Case report and review of the Literature. *Dig Dis Sci* 1992;37: 1141-4
12. Varsheney S. Johnson CD. Tuberculosis of the pancreas. *Postgrad Med J.* 1995: 71:564-6
13. Paustian FF. Tuberculosis of the intestine. In: Bockus HL, editor. *Gastroenterology, vol.11, 2nd ed. Philadelphia :W.B. Saunders Co.;* 1964 p.311.
14. Tassios P, Ladas S, Giannopoulos G, Larion K Katsogridakis J,Chalarelakis G, et al. Tuberculous esophagitis. Report of a case and review of modern approaches to diagnosis and treatment. *Hepatogastroenterology*1995; 42 : 185-8.
15. Ali W, Sikora SS, Banerjee D, Kapoor VK, Saraswat VA, Saxena R, et al. Gastroduodenal tuberculosis. *Aust NZ J Surg*1993; 63 : 466-7.
16. Gupta SK, Jain AK, Gupta JP, Agrawal AK, Berry K. Duodenal tuberculosis. *Clin Radiol*1988; 39 : 159-61.
17. Berney T, Badaoui E, Totsch M, Mentha G, Morel P. Duodenal tuberculosis presenting as acute ulcer perforation. *Am J Gastroenterol* 1998; 93 : 1989

18. Vij JC, Ramesh GN, Choudhary V, Malhotra V. Endoscopic balloon dilation of tuberculous duodenal strictures. *GastrointestEndosc* 1992; 38 : 510-1.
19. Chawla S, Mukerjee P, Bery K. Segmental tuberculosis of the colon: a report of ten cases. *Clin Radiol* 1971; 22 :104-9.
20. Arya TVS, Jain AK, Kumar M, Agarwal AK, Gupta JP. Colonic tuberculosis : a clinical and colonoscopic profile. *Indian J Gastroenterol* 1994; 13 (Suppl) A
21. Singh V, Kumar P, Kamal J, Prakash V, Vaiphei K, Singh K. Clinicocolonoscopy profile of colonic tuberculosis. *Am J Gastroenterol* 1996; 91 : 565-8.
22. Shaikh MS, Dholia KR, Jalbani MA: Prevalence of intestinal tuberculosis in cases of acute abdomen. *Pakistan J Surg* 2007, 23:52– 56.
23. Chowdhary GN, Dawar R, Misra MC. Coexisting carcinoma and tuberculosis of stomach. *Indian J Gastroenterol* 1999; 18 : 179-80
24. Kapoor VK. Abdominal tuberculosis : the Indian contribution. *Indian J Gastroenterol* 1998; 17 : 141-7.
25. Bhansali SK, Sethna JR. Intestinal obstruction : a clinical analysis of 348 cases. *Indian J Surg* 1970; 32 : 57-70.
26. Dorairajan LN, Gupta S, Deo SV, Chumber S, Sharma L. Peritonitis in India – a decade's experience. *Trop Gastroenterol* 1995; 16 : 33-8.
27. Ranjan P, Ghoshal UC, Aggarwal R, Pandey R, Misra A, Naik S, et al. Etiological spectrum sporadic malabsorption syndrome in Northern Indian adults at a tertiary hospital. *Indian J Gastroenterol* 2004; 23 : 94-8.
28. Puri AS, Vij JC, Chaudhary A, Kumar N, Sachdev A, Malhotra V, et al. Diagnosis and outcome of isolated rectal tuberculosis. *Dis Colon Rectum* 1996; 39 : 1126-9.
29. Dandapat MC, Mukherjee LM, Behra AN. Fistula in ano. *Indian J Surg* 1990; 52 : 265-8.
30. Shukla HS, Gupta SC, Singh C, Singh PA. Tubercular fistula in ano. *Br J Surg* 1988; 75 : 38-9.
31. Kapoor VK, Chattopadhyay TK, Sharma LK. Radiology of abdominal tuberculosis. *AustralasRadiol* 1988; 32 : 365-7.
32. Tandon RK, Sarin SK, Bose SL, Berry M, Tandon BN. A clinic radiological reappraisal of intestinal tuberculosis– changing profile? *Gastroenterol Jpn* 1986; 21 : 17-22.
33. Sharp JF, Goldman M. Abdominal tuberculosis in East Birmingham: A 16 year study. *Postgrad Med J* 1987; 63:539-42.
34. HK Ha, JI Jung, MS Lee, Choi BG, Lee MG, Kim YH. CT differentiation of tuberculosis peritonitis and peritoneal carcinomatosis. *Am J Roentgenol* 1996; 167: 743-8.
35. Bhargava DK, Kushwaha AKS, Dasarathy S, Shriniwas, Chopra P. Endoscopic diagnosis of segmental colonic tuberculosis. *GastrointestEndosc* 1992; 38 : 571-4.
36. Chawla TC, Sharma A, Kiran U, Bhargava DK, Tandon BN. Serodiagnosis of intestinal tuberculosis by enzyme immunoassay and soluble antigen fluorescent antibody tests using a saline extracted antigen. *Tubercle* 1986; 67 :55-60.
37. Sathar MA, Simjer AE, Coovadia YM, Soni PN, Moola SA, Insam B, et al. Ascitic fluid gamma interferon concentrations and adenosine

- deaminase activity in tuberculous peritonitis. *Gut* 1995; 36 : 419-21.
38. Dwivedi M, Misra SP, Misra V, Kumar R. Value of adenosine deaminase estimation in the diagnosis of tuberculous ascites. *Am J Gastroenterol* 1990; 85 : 1123-5.
39. Balasubramanian R, Ramachandran R, Joseph PE, Nagarajan M, Thiruvengadam KV, Tripathy SP, et al. Interim results of a clinical study of abdominal tuberculosis. *Indian J Tuberc* 1989; 36 : 117-21.
40. Arif AU, Shah LA, Ullah A, Sadiq MD: The frequency and management of intestinal tuberculosis; a hospital based study. *J Postgrad Med Instit* 2008, 22.
41. Balasubramanian R, Nagarajan M, Balambal R, Tripathy SP, Sundararaman R, Venkatesan P. Randomised controlled clinical trial of short course chemotherapy in abdominal tuberculosis: a five-year report. *Int J Tuberc Lung Dis* 1997; 1 : 44-51.
42. Pimparkar BD, Donde UM. Intestinal tuberculosis II. Gastrointestinal absorption studies. *J Assoc Physicians India* 1974; 22 : 219-28.
43. Gondal SH, Gulshan S, Naseeb U: Intestinal Tuberculosis as an abdominal emergency. *Pak Postgrad Med J* 2000, 11:103–105.
44. Baloch NA, Baloch MA, Baloch FA: A study of 86 cases of abdominal tuberculosis. *J Surg Pak* 2008, 13:30–32.
45. Chalya et al.: Clinicopathological profile and surgical treatment of abdominal tuberculosis: a single centre experience in northwestern Tanzania. *BMC Infectious Diseases* 2013 13:270.46. Anand BS, Nanda R, Sachdev GK. Response of tuberculous stricture to antituberculous treatment. *Gut* 1988; 29 :62-9
46. Pujari BD. Modified surgical procedures in intestinal tuberculosis. *Br J Surg* 1979; 66 : 180-1.
47. Bhansali SK. Abdominal tuberculosis. Experiences with 300 cases. *Am J Gastroenterol* 1977; 67 : 324-37.