



Hemiballism as a Presenting Symptom of Hyperglycemia in a Previously Undiagnosed Diabetic Patient: A Rare Case Scenario

¹Dr. Amogh S Chappalagavi, ²Dr. Danish Ahmad Khan, ³Dr. Mohammad Zahid Labrez, ⁴Dr. Ritika Raj

^{1,2}PG Scholar, Department of Medicine, Shri Krishna Medical College and Hospital, Muzaffarpur, Bihar, India

³Senior Resident, Department of Medicine, Shri Krishna Medical College and Hospital, Muzaffarpur, Bihar, India

⁴Intern, Shri Krishna Medical College and Hospital, Muzaffarpur, Bihar, India

Citation of this Article: Dr. Amogh S Chappalagavi, Dr. Danish Ahmad Khan, Dr. Mohammad Zahid Labrez, Dr. Ritika Raj, “Hemiballism as a Presenting Symptom of Hyperglycemia in a Previously Undiagnosed Diabetic Patient: A Rare Case Scenario.” IJMSAR – June – 2023, Vol. – 6, Issue - 3, Page No. 07-12.

Copyright: © 2023, Dr. Amogh S Chappalagavi, et al. This is an open access journal and article distributed under the terms of the creative commons attribution noncommercial License. This allows others to remix, tweak, and build upon the work non commercially, as long as appropriate credit is given and the new creations are licensed under the identical terms.

Corresponding Author: Dr. Amogh S Chappalagavi, PG Scholar, Department of Medicine, Shri Krishna Medical College and Hospital, Muzaffarpur, Bihar, India

Type of Publication: A Case Report

Conflicts of Interest: Nil

ABSTRACT

Hemichorea-hemiballismus is a rare but significant manifestation of chronic uncontrolled hyperglycemia that is especially seen in postmenopausal women.. This case study serves as an important reminder of the significance of identifying hyperglycemia as a probable hemiballismus aetiology. It is important to distinguish between other intracranial pathologies and hyperglycaemic intracranial alterations since quick glycaemic control in the latter can aid with hemiballistic symptoms and avoid a more aggressive

or invasive workup. Here, we offer a case report that looks at the clinical situations in which HH can manifest in people with diabetes. We also examine the literature that is currently available on this phenomenon in terms of its pathogenesis, diagnosis, and treatment.

Keywords

Diabetes, Hemichorea-hemiballismus, Hyperglycemia

INTRODUCTION

Movement disorders, such as ballismus or chorea, are

usually caused by an infarct/hemorrhage but rarely can appear as the first signs of diabetes mellitus in a patient or as a result of non-ketotic hyperglycemia in individuals who have already been diagnosed, particularly with type 2 diabetes mellitus. They are unusual symptoms that are far less frequently seen than stroke, seizures, comas, or sensory-motor polyneuropathies as consequences of diabetes mellitus, but if they are recognised, they must immediately be linked to blood glucose and glycosylated haemoglobin (HbA1C) readings. From the roughly 200 cases associated with non-ketotic hyperglycemia and these types of movement disorders that have been documented in the literature, adults with a mean age of 71 years and a female to male sex ratio of 1,8:1 were affected more frequently. These patients were primarily from eastern Asia, but also came from South America, the United States, and Europe. Hemiballismus or hemichorea are the terms used when these movement problems only affect one half of the body, as was the case in 90% of the cases studied. Chorea, hyperglycemia, basal ganglia (CHBG) syndrome, or later by other authors as non-ketotic hyperglycemic hemichorism, was first described by S.F. Bedwell in 1960 due to the transient changes seen, primarily a hyperintensity in the contralateral putamen and less frequently in the head

of the caudate nucleus on the T1 weighted magnetic resonance imaging (MRI) [1].

The onset of the symptoms might be sudden, gradual, or intense. If the condition is acute, the symptoms may begin with ballismus (violent, involuntary flinging, fidgety movements, with large amplitude, predominantly affecting the proximal part of the limbs) and then progress to chorea (mild/moderate irregular, involuntary, hyperkinetic, dance-like movements, with lower amplitude). The prognosis is fair; symptoms usually get better and fade away if nonketotic hyperglycemia is corrected (in a few days to weeks), but they occasionally return [2,3,4].

A very uncommon cause of hemichorea-hemiballism (HH) is hyperglycemia. Here, we offer a case report that looks at the clinical situations in which HH can manifest in people with diabetes. We also examine the literature that is currently available on this phenomenon in terms of its pathogenesis, diagnosis, and treatment.

CASE REPORT

A 65-year-old woman who had been experiencing uncontrollable, constant flinging movements of her right upper and lower limbs for three days came to our emergency department. Her everyday tasks were hampered by the movements, which only stopped when she slept. There was no prior trauma or stroke

history. She had a steady pulse of 80 beats per minute and blood pressure of 130/90 mmHg when examined. She had normal findings from her CNS evaluation except for the uncontrollable ballistic motions. Her lab tests revealed a random blood glucose level of 531 mg/dL, a normal arterial blood gas analysis, negative blood ketone levels, and a HbA1c level of 16.2%, which indicated a protracted period of undiagnosed

diabetes. A T1 hyperintensity was seen on brain MRI in the left lentiform nucleus. She was started on Haloperidol along with Biphasic Insulin and glycaemic control was optimized over 3 days, following which the involuntary movements subsided. The movements did not recur with the discontinuation of Haloperidol once good glycaemic control was achieved.

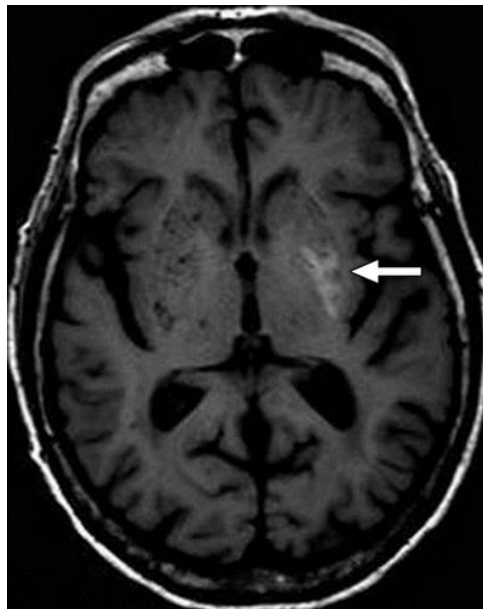


Figure 1: T1 weighted MRI showing hyperintensity in the left lentiform nucleus

She was identified as having hemiballismus/hemichorea based on the history of uncontrolled hyperglycemia and the results of the MRI scan. Her blood sugar level was closely monitored. The patient's uncontrollable motions got better once her blood sugar levels were controlled.

DISCUSSION

A high-amplitude, proximal ballistic tossing motion known as hemiballismus affects the limbs on one side of the body. The loss of thalamic inhibition that results from a lesion (often an infarction or haemorrhage) in the subthalamic nucleus is thought to be the

mechanism of hemiballism, leading to excessive motor activity on the opposite side [5,6]. A rare cause of hemiballism, non-ketotic hyperglycemia is typically observed in older women [7]. In a 15-year study of all patients with chorea/ballismus at the Mayo Clinic, just 1% of individuals had hyperglycemia as the underlying cause, underscoring the condition's rarity [8]. The generally accepted idea to explain this behaviour is that hyperglycemia causes blood to become more viscous, which reduces blood flow, and that this increases anaerobic metabolism, which depletes GABA and increases thalamocortical activity [9]. Since the irregular movements are frequently quickly resolved, it is crucial to diagnose and treat hyperglycemia as soon as possible. We were able to rule out common causes of hemiballism thanks to clinical history and examinations, and the elimination of involuntary movements by prompt glycemic management further supported our diagnosis [10].

On MRI, elevated blood glucose levels and hyperintense striatum are detected in nearly all of the patients who present with non-ketotic hyperglycemic-associated hemichorea/hemiballismus. These patients' striatal (putamen) hyperintensity and hyperdensity can be shown on the brain's MRI and CT scans, respectively [11]. Our patient displayed typical

hemichorea/hemiballismus symptoms associated with non-ketotic hyperglycemia, and her CT scan of the head did not reveal any abnormality. A stat MRI was done since it was thought she might have had a stroke; the results pointed more towards inflammatory or infectious alterations than glial neoplasm or haemorrhage. The patient was uncooperative and aggressive, so a lumbar puncture (LP) was performed under general anaesthesia based on the results of the MRI. The CSF analysis was within acceptable bounds. Meanwhile, based on the results of a repeat CT head and her medical history, she was identified as having non-ketotic hyperglycaemic - associated hemichorea/hemiballismus. Because the symptoms typically go away after the correction of glucose derangements, it is crucial that doctors are aware of the presenting symptoms of non-ketotic hyperglycaemic-associated hemichorea/hemiballismus and avoid aggressive and invasive workup when they encounter a diabetic patient presenting with hyperkinetic disorders. To treat the symptoms, dopamine depletion medications such haloperidol or tetrabenazine [12], as well as infrequently repeated transcranial magnetic stimulation or deep brain stimulation [13, 14] in refractory cases, may be necessary. Chorea symptoms often go away completely between six months to a

year, but can occasionally last for one to two years [15].

CONCLUSIONS

In light of its excellent prognosis and complete reversibility with glycemic control, hyperglycaemic hemiballism should be considered as a differential diagnosis in patients who present with ballistic or choreic movements. This case highlights the significance of suspecting undiagnosed prolonged diabetes in such patients. In our case, non-ketotic hyperglycemia was observed to be accompanied by hemiballismus and hemichorea. When treating diabetic patients, doctors should keep this potential cause of hemiballismus or hemichorea in mind because early diagnosis can avoid needless and intrusive treatments.

REFERENCES

1. Bedwell SF. Some observations on hemiballismus. *Neurology* 1960;10:619-622.
2. Su S, Gaillard FR. Non-ketotic-hyperglycaemic-hemichorea. www.radiopaedia.org.
3. Pham K, Meegada S et al. Hemichorea Induced by Non-ketotic Hyperglycemia in a Caucasian Woman. *Cureus J Med Sci* 2020;12(2): e6866.
4. Danve A, Kulkarni S, Bhoite G. Non-ketotic hyperglycemia unmasks hemichorea. *J Comm Hospital Internal Med Perspectives*. Sep. 2015; 5(4):1-5. 27825.
5. Dewey RB, Jankovic J. Hemiballismus-hemichorea Clinical and pharmacologic findings in 21 patients. *Arch Neurol* 1989;46:862-7.
6. Postuma RB, Lang AE. Hemiballismus: revisiting a classic disorder. *Lancet Neurol* 2003;2:661-8.
7. Oh SH, Lee KY, Im JH, et al. Chorea associated with non-ketotic hyperglycemia and hyperintensity basal ganglia lesion on T1-weighted brain MRI study: a meta-analysis of 53 cases including four present cases. *J Neurol Sci* 2002;200:57-62.
8. Ifergane G, Masalha R, Herishanu YO. Transient hemichorea/hemiballismus associated with new onset hyperglycemia. *J Can Sci Neurol*. 2001;28(4):365-368.
9. Bathla G, Policeni B, Agarwal A. Neuroimaging in patients with abnormal blood glucose levels. *AJNR Am J Neuroradiol* 2013 May 2.
10. Wilson Thomas J, et al. Non-ketotic hyperglycemic chorea-hemiballismus mimicking basal ganglia hemorrhage. *J Clin Neurosci*. 2011; 18(11): 1560-1561.
11. Cosentino C, Torres L, Nuñez Y, Suarez R, Velez M, Flores M: Hemichorea/hemiballism associated

- with hyperglycemia: report of 20 cases. Tremor Other Hyperkinet Mov (N Y). 2016, 6:402-2016.
12. Lin YT, Chen SC, Yip PK, Wang V: Magnetic resonance imaging volumetric analysis for diabetic striatopathy with two episodes of hemichorea-hemiballism syndrome: a case report. Medicine (Baltimore). 2019, 98:e17249.
13. Kaseda Y, Yamawaki T, Ikeda J, et al.: Amelioration of persistent, non-ketotic hyperglycemia-induced hemichorea by repetitive transcranial magnetic stimulation. Case Rep Neurol. 2013, 5:68-73.
14. Son BC, Choi JG, Ko HC: Globus pallidus internus deep brain stimulation for disabling diabetic hemiballism/hemichorea. Case Rep Neurol Med. 2017.
15. Roy U, Das SK, Mukherjee A, et al.: Irreversible Hemichorea-Hemiballism in a Case of NonketoticHyperglycemia Presenting as the Initial Manifestation of Diabetes Mellitus. Tremor Other HyperkinetMov N Y. 2016;6, 393-2016.