



A Rare Manifestation of a Common Vector Borne Disease

¹Dr. Salony Mittal, ²Dr. Jyoti Mishra, ³Dr. Samriddhi Allahabadi

^{1,2}Associate Professor, Department of Pathology, School of medical Sciences and Research, Sharda University, Greater Noida, Uttar Pradesh, India

³PG Scholar, Department of Pathology, School of medical Sciences and Research, Sharda University, Greater Noida, Uttar Pradesh, India

Citation of this Article: Dr. Salony Mittal, Dr. Jyoti Mishra, Dr. Samriddhi Allahabadi, “A Rare Manifestation of a Common Vector Borne Disease,” IJMSAR – August – 2022, Vol. – 5, Issue - 4, Page No. 23-26.

Copyright: © 2022, Dr. Salony Mittal, et al. This is an open access journal and article distributed under the terms of the creative commons attribution noncommercial License. This allows others to remix, tweak, and build upon the work non commercially, as long as appropriate credit is given and the new creations are licensed under the identical terms.

Corresponding Author: Dr. Salony Mittal, Associate Professor, Department of Pathology, School of medical Sciences and Research, Sharda University, Greater Noida, Uttar Pradesh, India

Type of Publication: A Case Report

Conflicts of Interest: Nil

Abstract

Hemophagocytic lymphohistiocytosis may occur secondary to Dengue fever. Though rare, its possibility should be kept in mind if the fever and/or peripheral blood cytopenias persist in a child with Dengue fever. Its timely diagnosis with intravenous steroid therapy can be life saving. We intend to report a similar case of 11 years old child which on strong clinical suspicion was timely planned for bone marrow aspiration.

Introduction

Dengue fever is a common vector borne disease may have lethal complications. Severe dengue is a hyperinflammatory condition excess of cytokines can lead to hemophagocytic lymphohistiocytosis. Its early clinical suspicion can be lifesaving. We encountered one such case in a 11 years old child

which on strong clinical suspicion was timely planned for bone marrow aspiration.

Case

A 11 years old child presented to OPD with history of fever, frequent episodes of vomiting and decreased appetite for 1 day. It was acute in onset, high grade and continuous in nature. The fever was not associated rash/chills/rigors/ bleeding or any other clinical symptoms.. There was no significant past, drug history or history of any other chronic illness. On examination, the general condition was fair and blood pressure was 106/67 mmHg, sPO2- 98% on room air, the respiratory rate was 28/min and temperature was 100°F. There was no pallor/ cyanosis/icterus/clubbing/edema/lymphadenopathy. There was no organomegaly or lymphadenopathy.

Initial fever work up showed NS1 antigen positive. So, patient was managed conservatively for Dengue fever with no warning signs, but fever persisted for 6 days despite of the treatment. Further fever workup was done and investigations were sent in view of the same which suggested persistent thrombocytopenia. On day 7, highest spike of fever was recorded as 104°F after which patient experienced respiratory distress in the form of increased work of breathing followed by escalating need of oxygen

support. Arterial Blood gas analysis revealed respiratory acidosis. Chest X ray showed bilateral reticular nodular opacities (left side >right).Respiratory support was increased from Oxygen to High flow nasal cannula followed by intubation and he was put on Positive Pressure Ventilation as he worsened. Steroids were started in view of sepsis. The patient was thoroughly investigated and all the results are shown in Table1.

Table 1: Investigations done in the case

Complete Blood Count	Liver function tests	Renal function tests	Electrolytes	Other tests
Day 6	Total Bilirubin-	Urea- 40.50 mg/dl	Na+=149.00	CRP- 43mg/dl
Hb – 10.0 g/dl	1.26 mg/dl		mEq/L	
RBC Count-	Direct=0.53	Creatinine- 0.40		Serum Ferritin-
4.52millions/cumm	Indirect=0.73	mg/dl	K+= 3.40	>1000mg/ml
TLC-2.54x10 ³ /cumm			mgEq/L	
DLC- Neutrophils-65%	SGOT=49.50	Uric Acid- 2.00		Serum
Lymphocytes-28%	U/L	mg/dl	Cl- = 111.0	Triglycerides-
Monocytes =01%	SGPT=116 U/L		mgEq/L	308mg/dl
Eosinophils=06%				
MCV- 83.2 fl	ALP=112.0 U/L		Serum Ca=	
MCH- 28.8 pg			8.80mg/dl.	
MCHC- 34.6%				
Platelet count-	Total Protein-			
1,00,000/cum.	7.10 g/d			
Peripheral smear findings showed mild normocytic normochromic anemia with thrombocytopenia.				

Due to persistent fever and thrombocytopenia, bone marrow aspiration with biopsy was also done. The blood culture reports were also negative and showed no growth.

Bone marrow aspirate (Figure 1) and biopsy sections (Figure 2) revealed increased number of macrophages which showed phagocytosed blood cells (platelets, granulocytes).The diagnosis of hemophagocytosis was established. The findings of bicytopenia, hypertriglyceridemia, hypofibrinogenemia, hemophagocytosis in bone marrow and increased ferritin levels confirmed the case to be hemophagocytic lymphohistiocytosis secondary to dengue.

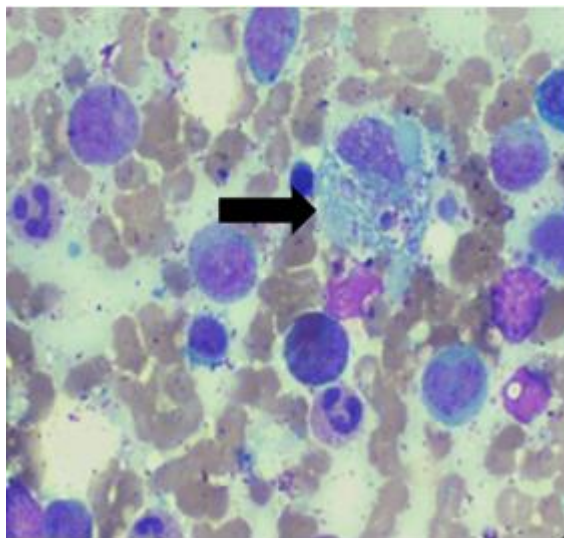


Figure 1: A macrophage engulfing platelet shown by arrow in bonemarrow aspirate (40x).

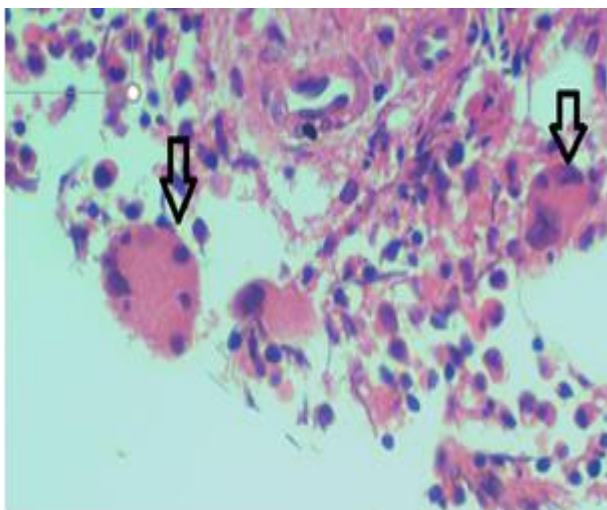


Figure 2: Hemophagocytosis in bone marrow biopsy (40 x)

Discussion

Hemophagocytosis refers to engulfment^[1] of red blood cells, lymphocytes and other hemotopoetic cells by macrophages in bone marrow and other hematopoetic organs like liver, spleen, etc. It has varied causes which include infections, inflammation, malignancies, conditions pertaining to marrow hyperplasia or ineffective haematopoiesis. Hemophagocytic lymphohistiocytosis (HLH) is hyperinflammatory condition, in which cytokine storm

leads to uncontrolled proliferation of phagocytic cells and progression to organ dysfunction. It can be primary or secondary to viral infections, autoimmune conditions or malignancies^[2,3]. Ebstein Barr virus is the most common infection causing HLH. The diagnosis of HLH should be prompt as any delay in detection can be life threatening. Dengue virus, a flavivirus can also cause HLH and the documented mortality is 43% in dengue associated HLH. However,

its diagnosis is challenging as it can be confused with sepsis clinically. To establish the diagnosis of HLH, minimum 5 out of 8 criteria should be fulfilled which includes fever, splenomegaly, bicytopenia/pancytopenia, ferritin $\geq 500 \mu\text{g/L}$, increased triglyceride levels and/or hypofibrinogenemia, hemophagocytosis in bone marrow or spleen or lymph nodes, low or absent NK-cell activity, and increased levels of soluble CD25^[4,5]. Due to persistent pancytopenia, this patient was strongly suspected of secondary HLH. The bone marrow aspirate smears and biopsy sections showed presence of hemophagocytic activity which supported our diagnosis of hemophagocytic lymphohistiocytosis. He responded well with systemic steroids and showed resolution of fever with improvement of blood parameters as well. Though, dengue associated HLH is a known complication but it is relatively rare and that too in pediatric age group is less common^[6,7]. This insisted us to add our case to the literature. Certain hints like persistent pancytopenia and fever in a child suffering from dengue should prompt to Dengue associated HLH. Thus, early recognition of HLH and prompt intervention can be life saving.

References

1. Chandra H, Chandra S, Kaushik R, Bhat N, Shrivastava V. Hemophagocytosis on bone marrow aspirate cytology: single center experience in north himalayan region of India. *Ann Med Health Sci Res.* 2014 Sep;4(5):692-6.
2. Bain BJ, Clark DM, Wilkins BS, editors. *Bone Marrow Pathology.* 4th ed. Oxford: Wiley Blackwell Publishing; 2010. Infection and reactive changes; pp. 137–44.
3. Unal S, Cetin M, Kutlay NY, Elmas SA, Gumruk F, Tukun A, et al. Hemophagocytosis associated with leukemia: A striking association with juvenile myelomonocytic leukemia. *Ann Hematol.* 2010;89:359–64.
4. Chang CY, Rajappan M, Zaid M, Ong ELC. Dengue fever complicated by hemophagocytic lymphohistiocytosis: Report of 2 cases and bone marrow findings. *Clin Case Rep.* 2020 Oct 27;8(12):3427-3431. doi: 10.1002/ccr3.3422. PMID: 33363946; PMCID: PMC7752383.
5. Chung, Sang Mi MD; Song, Joon Young MD, PhD; Kim, Wonshik MD; Choi, Min Joo MD; Jeon, Ji Ho MD; Kang, Seonghui MD; Jung, Eunju MD; Noh, Ji Yun MD, PhD; Cheong, HeeJin MD, PhD; Kim, Woo Joo MD, PhD. Dengue-associated hemophagocytic lymphohistiocytosis in an adult: A case report and literature review. *Medicine: February 2017 - Volume 96 - Issue 8 - p e6159*
6. Munshi A, Alsuraihi A, Balubaid M, Althobaiti M, Althaqafi A. Dengue-Induced Hemophagocytic Lymphohistiocytosis: A Case Report and Literature Review. *Cureus.* 2021 Dec 5;13(12):e20172. doi: 10.7759/cureus.20172. PMID: 35003998; PMCID: PMC8724679.
7. Thadchanamoorthy V, Dayasiri K. Dengue Fever Associated Haemophagocytic Lymphohistiocytosis: A Report of Two Children. *Cureus.* 2020 Oct 29;12(10):e11232. doi: 10.7759/cureus.11232. PMID: 33269160; PMCID: PMC7704164.